

EXPERIMENTAL INFECTION OF WHITE-TAILED DEER (*ODOCOILEUS VIRGINIANUS*) WITH *MYCOBACTERIUM AVIUM* SUBSP. *PARATUBERCULOSIS*

Mitchell V. Palmer,^{1,3} Judith R. Stabel,¹ W. Ray Waters,¹ John P. Bannantine,¹ and Janice M. Miller²

¹ Bacterial Diseases of Livestock Research Unit, National Animal Disease Center, USDA, Agricultural Research Service, 2300 Dayton Avenue, Ames, Iowa 50010, USA

² Virus and Prion Diseases Research Unit, National Animal Disease Center, USDA, Agricultural Research Service, 2300 Dayton Avenue, Ames, Iowa 50010, USA

³ Corresponding author (email: mitchell_palmer@ars.usda.gov)

ABSTRACT: *Mycobacterium avium* subsp. *paratuberculosis* (Map) is the causative agent of paratuberculosis or Johne's disease, a chronic enteric disease of domestic ruminants as well as some nondomestic ruminants. Paratuberculosis is characterized by a protracted subclinical phase followed by clinical signs such as diarrhea, weight loss, and hypoproteinemia. Fecal shedding of Map is characteristic of both the subclinical and clinical phases, and it is important in disease transmission. Lesions of paratuberculosis are characterized by chronic granulomatous enteritis and mesenteric lymphadenitis. Animal models of paratuberculosis that simulate all aspects of the disease are rare. Oral inoculation of 9-day-old white-tailed deer (*Odocoileus virginianus*) on 3 June 2002 with 1.87×10^{10} colony-forming units of Map strain K10 resulted in clinical disease (soft to diarrhetic feces) as early as 146 days after inoculation; lesions consistent with paratuberculosis were observed in animals at the termination of the study. Intermittent fecal shedding of Map was seen between 28 and 595 days (4 March 2004) after inoculation. These findings suggest that experimental oral inoculation of white-tailed deer fawns may mimic all aspects of subclinical and clinical paratuberculosis.

Key words: Johne's disease, *Mycobacterium avium* subsp. *paratuberculosis*, *Odocoileus virginianus*, paratuberculosis, white-tailed deer.

INTRODUCTION

Mycobacterium avium subsp. *paratuberculosis* (Map) is the causative agent of paratuberculosis or Johne's disease. Paratuberculosis in ruminants is characterized by chronic, progressive enteritis, and it is often accompanied by protracted diarrhea and weight loss. Paratuberculosis is generally associated with domestic ruminants such as cattle, sheep, and goats with sporadic occurrence in free-ranging ruminants such as white-tailed deer (*Odocoileus virginianus*) (Libke and Walton, 1975; Chiodini and Van Kruiningen, 1983), tule elk (*Cervus nannodes*) (Jessup et al., 1981), bighorn sheep (*Ovis canadensis*), Rocky Mountain goats (*Oreamnos americanus*) (Williams et al., 1983b), bison (*Bison bison*) (Buergelt et al., 2000), and Key deer (*Odocoileus virginianus clausenianus*) (Quist et al., 2002).

Paratuberculosis has been diagnosed in both free-ranging and captive white-tailed deer in the United States (Chiodini and Van Kruiningen, 1983; Davidson et al., 2004; Hattel et al., 2004). There has been increasing interest in paratuberculosis in deer with the growth of the deer farming industry and interest in diseases that may be transmitted between domestic animals and wildlife.

New Zealand has the largest number of farmed deer of any country with most deer being red deer (*Cervus elaphus*) or red deer/elk hybrids (Mackintosh et al., 2004). Paratuberculosis has been identified as a serious problem in New Zealand farmed deer where the herd prevalence is approximately 6% (deLisle et al., 2003). In contrast to New Zealand, deer farming is a relatively new industry in the United States. Diagnostic tests, vaccines, and therapies for maladies affecting captive

deer are generally not specifically designed for deer but extrapolated from practices used with domestic ruminant species. Medical advances benefiting both captive and free-ranging deer will require the use of animal models of disease, preferably using the host species of interest. Models of paratuberculosis have been reported in sheep (Kluge et al., 1968; Begara-McGorum et al., 1998), goats (Storset et al., 2001), cattle (Waters et al., 2003; Sweeney et al., 2006), bison (Stabel et al., 2003), and red deer (O'Brien et al., 2006). Although most models succeed at reproducing subclinical disease, few models simulate subclinical and clinical disease, lesion development, and fecal shedding of Map.

Although paratuberculosis has been extensively studied in domestic ruminants, descriptions of the clinical, pathologic, and immunologic aspects of the disease in white-tailed deer are limited (Williams et al., 1983a, 1985). Clinical disease characterized by soft to diarrheic feces, poor hair coat, and poor body condition have been described in experimentally infected white-tailed deer (Williams et al., 1983a). Multiple tissues from experimentally infected deer contained Map; however, fecal shedding of Map was not detected. Clinical disease has been reported in a single naturally infected white-tailed deer fawn characterized by anorexia, emaciation, watery diarrhea, and death (Libke and Walton, 1975).

The objective of the current study was to investigate a potential model system of paratuberculosis in white-tailed deer that would simulate natural paratuberculosis in its clinical nature, immune response, lesion distribution, lesion character, and presence of fecal shedding. Such a model system could prove useful in development of improved diagnostic assays, vaccine evaluation, and the examination of intraspecies and interspecies transmission as well as methods to mitigate transmission.

MATERIALS AND METHODS

Animals

Four female white-tailed deer were removed from their dams 24–36 hr after birth. At birth, fawns received parenteral vitamin A/D and selenium. Deer were part of a research herd at the National Animal Disease Center (NADC) in Ames, Iowa, USA (42°3'N, 93°63'W). This research herd has had no history of paratuberculosis since its foundation in 1998. All deaths within the herd are examined by thorough postmortem examination, including microscopic evaluation of tissues, which regularly include the distal ileum and ileocecal lymph nodes. During the experimental period, from 3 June 2002 to 4 March 2004, deer were housed together, but they were isolated from other animals in a pen approximately 16 m² and located inside a bio-safety level 2 building with directional airflow to prevent room-to-room transfer of air. Airflow velocity was adjusted to provide 10.4 air changes/hr in each animal pen. Deer had access to a circulating watering device, and they were fed a commercial milk replacer (Kid Milk Replacer, Purina Mills, St. Louis, Missouri, USA) according to a standard white-tailed deer feeding regimen. After weaning, deer were fed pelleted feed (Deer and elk complete feed 55P3, Purina Mills). Animals were observed twice daily by animal care or veterinary staff. A protocol detailing experimental procedures and animal care was approved by the Institutional Animal Care and Use Committee before the experiment.

Inoculation

At 9 days of age, all fawns received a single oral dose of 1.87×10^{10} colony-forming units (CFU) of Map strain K10 (NADC). Strain K10 is a virulent, low passage strain, originally isolated from a clinical dairy cow, and it is the strain from which the complete genome sequence of Map was determined (Li et al., 2005). To ensure complete consumption of the inoculum, all deer received the inoculum in 30 ml of milk replacer. Immediately after consuming the challenge inoculum, fawns were fed the remainder of the milk replacer for a single feeding (ca. 90–150 ml).

Inoculum

Mycobacterium avium subsp. *paratuberculosis* strain K10 was propagated in M7H9 medium with albumin, dextrose, catalase, and oleic acid (BD Biosciences, Franklin Lakes, New Jersey, USA) and 2 mg/l mycobactin J

(Allied Monitor, Fayetteville, Missouri, USA) and harvested in the log phase of growth. Bacteria were pelleted by centrifugation at $750 \times G$, washed with 0.15 M phosphate-buffered saline (PBS; pH 7.4) two times, and resuspended in sterile PBS. Enumeration of bacilli was by serial dilution plate counting. Inoculum was stored in 1-ml aliquots at -80 C until use. Twenty-four hours after freezing, a single 1-ml aliquot was removed, and bacilli were enumerated by plate counting of serial dilutions. At the time of inoculation, aliquots of inoculum were thawed and then diluted to the appropriate concentration based on plate counts as described above to a final concentration of 2.08×10^{10} /ml. Viability was assessed at approximately 90% using the Live/Dead BacLight kit (Invitrogen, Carlsbad, California, USA). Adjusting for viability, final inoculum counts were determined to be 1.87×10^{10} /ml. Plate counts were repeated the day of inoculation to retrospectively confirm inoculum dosage.

Sampling

Feces were collected from each fawn before inoculation (day 0) and on days 1–11, 28, 42, 53, 70, 84, 114, 147, 166, 196, 226, 256, 286, 316, 346, 381, 410, 440, 470, 505, 540, 568, and 595 after inoculation. Fecal samples were processed for isolation of Map as described previously (Stabel, 1997). Scoring of fecal shedding was done according to the following scheme: 0 (no Map isolated from fecal sample), 1 (1–10 CFU/g feces), 2 (11–50 CFU/g feces), and 3 (>50 CFU/g feces). Ten milliliters of heparinized blood and 10 ml of blood without anticoagulant were collected from each fawn before inoculation (day 0) and on days 15, 28, 42, 53, 70, 84, 114, 147, 166, 196, 226, 256, 286, 316, 346, 381, 410, 440, 470, 505, 540, and 568 after inoculation. Samples were processed for interferon (IFN)- γ and enzyme-linked immunosorbent assay (ELISA) as described below. Blood was collected using manual restraint, or, when necessary, deer were anesthetized by i.m. injection of a combination of 2 mg/kg xylazine and 6 mg/kg ketamine. After inoculation, the effects of xylazine were reversed by i.v. injection of 4 mg/kg tolazoline.

IFN- γ analysis

For each deer, at each time point, 1.5 ml of heparinized blood was dispensed into separate 2-ml microcentrifuge tubes containing 0.1 ml each of *M. avium* purified protein derivative (PPD) (PPDa; 20 $\mu\text{g}/\text{ml}$ final concentration), whole cell sonicates (WCS) of Map strain

19698 (20 $\mu\text{g}/\text{ml}$ final concentration; NADC), Map strain K10 (20 $\mu\text{g}/\text{ml}$ final concentration) pokeweed mitogen (PWM) (10 $\mu\text{g}/\text{ml}$ final concentration), and PBS. Whole cell sonicates were prepared as described previously (Waters et al., 2003). Samples were processed and analyzed as described for antigen-specific production of IFN- γ (Palmer et al., 2004). Briefly, after adding PPD, WCS, PWM, or PBS, tubes were capped, mixed by inversion or gentle vortexing, and incubated for 48 hr at 37 C in a humidified chamber with 5% CO_2 . After incubation, samples were centrifuged, and plasma was collected and stored at -20 C until analyzed. Plasma samples were analyzed for the presence of cervine IFN- γ using a commercially available sandwich enzyme immunoassay kit (CervigamTM, Prionics AG, Schlieren, Switzerland) according to manufacturer's instructions. Optical density (OD) measurements were analyzed in duplicate at 450 nm using an automated microplate reader (Molecular Devices, Menlo Park, California, USA). Previous research in white-tailed deer has shown PWM to be a superior mitogen compared with concanavalin A or phytohemagglutinin (Palmer et al., 2004).

Enzyme-linked immunosorbent assay

Antibodies to Map were detected using an ELISA for antibody to lipoarabinomannan (LAM)-enriched mycobacterial antigen preparations as described previously (Waters et al., 2002). Lipoarabinomannan-enriched mycobacterial antigen was prepared from Map strain K10, and the ELISA was performed as described previously (Waters et al., 2002). The absorbance (450 nm) of individual wells was measured using an automated ELISA plate reader (Molecular Devices). Data are presented as ΔOD calculated by subtracting the mean OD readings for wells receiving coating buffer alone (two replicates) from the mean OD readings for antigen-coated wells (two replicates) receiving the same serum sample. For comparison, serologic responses also were evaluated by a commercially available kit (IDEXX Laboratories, Westbrook, Maine, USA) according to manufacturer's instructions.

Necropsy

Fifteen days after inoculation, fawn 508 was euthanized subsequent to a handling-related injury. Samples of duodenum, jejunum, ileum, and ileocecal lymph node were collected for bacteriologic isolation of Map. Tissue samples were not collected for microscopic analysis.

Three hundred and ninety days after inoculation, fawn 504 was euthanized subse-

quent to a handling-related injury. Six hundred and fifty eight days after inoculation, the remaining deer (503 and 505) were euthanized and examined. Tissues collected from deer 503, 504 and 505 for bacteriologic isolation of Map and microscopic examination included palatine tonsil; mandibular, parotid, medial retropharyngeal, tracheobronchial, mediastinal, hepatic, duodenal, jejunal, ileocecal, and colic lymph nodes; and duodenum, jejunum, ileum, ileocecal valve, cecum, colon, lung, liver, kidney, spleen, and brain.

Bacteriologic culture of tissues was done as described previously (Stabel et al., 2003). Tissue samples were weighed and homogenized in 0.75% hexadecylpyridinium chloride solution (Sigma-Aldrich, St. Louis, Missouri, USA) by use of a stomacher for 1 min, and samples were allowed to stand overnight to decontaminate cultures. Dilutions of individual tissue homogenates were cultured by placing 100 μ l of diluted tissue homogenate onto agar slants of Herrold's egg yolk medium containing 2 mg/l mycobactin J (Allied Monitor). After 12 wk of incubation at 37 C, viable organisms were determined by enumerating colonies on agar slants. Tissues collected for microscopic analysis were fixed by immersion in 10% neutral buffered formalin and processed routinely to paraffin blocks. Sections were cut at a thickness of 5 μ m, and they were stained with hematoxylin and eosin (H&E). Adjacent sections also were cut and stained by the Ziehl-Neelsen technique for visualization of acid-fast bacteria.

Polymerase chain reaction (PCR)

Confirmation of Map colonies on agar slants was done by PCR to amplify the Map-specific genetic element *IS900* as described previously (Stabel et al., 2003). Primer sequences used in the reaction mixture were 5'-CCGCTAATTGAGAGATGCGATTGG-3' (forward primer) and 5'-AATCAACTCCAGCAGCGCGCC-TCG-3' (reverse primer), to yield a 229-base pair product. Negative controls consisted of reaction mixture alone, whereas positive controls consisted of 1 μ l of genomic DNA from Map and tubes with 5 μ l of Map DNA extracted from tissue samples from known positive cattle. Samples were considered positive when a band of expected size was visualized.

RESULTS

Clinical signs and shedding of Map

Clinical signs were seen in deer 503 and 505, which were euthanized 658 days after

inoculation. In both deer, a rough hair coat with multifocal alopecia was seen beginning at approximately 417 days after inoculation and persisting to the end of the study. Soft to diarrheic feces were seen in deer 505 beginning 146 days after inoculation, continuing to the termination of the study, with the exception of a 2–3-wk period 540 days after inoculation when formed feces was produced. Soft to diarrheic feces were seen in deer 503 beginning 505 days after inoculation and persisting to the end of the study.

Map was isolated from feces of all four deer at various times up to 4 days after inoculation. Intermittent shedding of Map continued in the three remaining deer from 28 days after inoculation to the time of euthanasia, including many time points when Map was recovered at >50 CFU/g feces (Fig. 1). Between 147 and 595 days after inoculation, deer 503 and 505 shed Map at a level of >50 CFU/g feces at 8/15 and 10/15 of the sampling times, respectively.

Post-mortem examination

No gross lesions consistent with paratuberculosis were seen in deer 508 (euthanized 15 days after inoculation). However, Map was isolated from the duodenum, jejunum, ileum, and ileocecal valve (Table 1). Similarly, no gross lesions were present in deer 504 (euthanized 390 days after inoculation); however, Map was isolated from numerous tissues of the gastrointestinal tract extending from the jejunum to the colon. Of note, Map was isolated in numbers too numerous to count (TNTC; >100 CFU) in both the ileum and colon. Gross lesions in deer 503 and 505 were characterized by loss of body fat, liquid intestinal contents, mild thickening of ileal mucosa, and moderate to marked enlargement of jejunal and ileocecal lymph nodes.

In tissues from deer 503, 504, and 505, microscopic lesions consistent with paratuberculosis were seen in various regions of the gastrointestinal tract

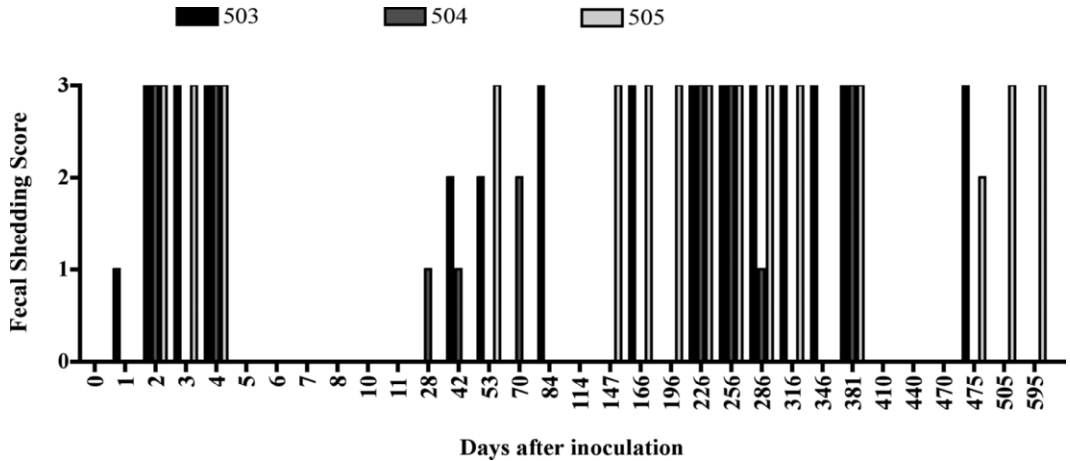


FIGURE 1. Fecal shedding scores of white-tailed deer orally inoculated with 1.87×10^{10} colony-forming units (CFU) of *Mycobacterium paratuberculosis* subsp. *paratuberculosis* (Map): 0=no Map isolated from fecal sample, 1=1–10 CFU/g feces, 2=11–50 CFU/g feces, and 3=>50 CFU/g feces. Day 0 represents the day of inoculation.

ranging from the jejunum to the colon and associated mesenteric lymph nodes as well as in the palatine tonsils and medial retropharyngeal lymph nodes (Table 1). Microscopic analysis revealed lesions similar in character in all affected tissues but differing in severity. Lesions in the intestine were characterized by villous atrophy combined with multifocal to coalescent infiltrations of macrophages and Langhans type multinucleated giant cells that expanded the lamina propria and formed multifocal granulomas within submucosal lymphoid tissue (Fig. 2). Many coalescent granulomas contained central areas of necrosis. Granulomatous infiltrations were invariably accompanied by numerous intracellular acid-fast bacteria in macrophages and occasionally multinucleated giant cells. Affected lymph nodes contained multifocal to coalescent infiltrations of macrophages and multinucleated giant cells that occupied both the cortex and medulla. In the jejunal lymph node of deer 505, coalescent corticomedullary granulomas contained multifocal lakes of acicular clefts (cholesterol clefts).

IFN- γ analysis

Only deer 503 developed a measurable IFN- γ response to PPDa or WCS of Map strains K10 and 19698 after experimental inoculation (Fig. 3). Elevated levels of IFN- γ were seen to all three antigens beginning 114 days after inoculation and persisting to 196 days after inoculation. Deer 504 and 505 did not develop measurable responses to Map, WCS, or PPDa, although deer 505 but not deer 504 developed an IFN- γ response to PWM similar to that seen in deer 503 (data not shown). Minimal IFN- γ responses were seen from deer 504 to any of the antigens, including PWM.

Enzyme-linked immunosorbent assay

Elevated antibody responses were detected by both the commercial ELISA and the LAM-enriched antigen ELISA beginning on day 50 (LAM-enriched ELISA) or day 114 (commercial ELISA) (Figs. 4, 5). All three deer (503, 504, and 505) developed antibodies to the LAM-enriched antigen (Fig. 5) where antibody titers persisted to the end of the study in deer 503 and 505, but declined to negligible

TABLE 1. Summary of lesion distribution and distribution of tissues from which *Mycobacterium avium* subsp. *paratuberculosis* (Map) was successfully isolated by bacteriologic culture.

Tissue	Animal identification ^a			
	503	504 ^b	505	508 ^c
Palatine tonsil	M,B (TNTC)	B (0.25)	M,B (TNTC)	–
Mandibular LN ^d	B (0.25)	–	B (12.0)	–
Parotid LN	B (1.50)	–	B (6.75)	–
Medial retropharyngeal LN	M,B (TNTC)	–	M,B (TNTC)	–
Tracheobronchial LN	B (1.75)	–	B (TNTC)	–
Mediastinal LN	B (TNTC)	–	B (38.25)	–
Lung	B (7.75)	–	B (36.25)	–
Liver	–	–	B (TNTC)	–
Hepatic LN	B (44.25)	–	M,B (TNTC)	–
Duodenum	B (TNTC)	–	B (TNTC)	B (1.50)
Duodenal LN	M,B (TNTC)	–	M,B (TNTC)	–
Jejunum	M,B (TNTC)	B (0.50)	M,B (TNTC)	B (1.75)
Jejunal LN	M,B (TNTC)	M,B (1.75)	M,B (TNTC)	–
Distal ileum	M,B (TNTC)	M,B (TNTC)	M,B (36.75)	B (11.25)
Ileocecal LN	M,B (TNTC)	M,B (35.25)	M,B (TNTC)	–
Ileocecal valve	M,B (TNTC)	M,B (14.25)	M,B (2.18)	B (0.50)
Colon	B (TNTC)	M,B (TNTC)	M,B (TNTC)	–
Colic LN	M,B (TNTC)	M,B (13.25)	M,B (TNTC)	–
Spleen	B (0.25)	–	–	–
Brain	B (25.0)	–	B (23.0)	–
Kidney	–	–	B (2.50)	–

^a Data (numerical) represent mean number of colonies of four different agar slants per gram of tissue processed for bacteriologic isolation. (TNTC) = colonies too numerous to count; >100 colony-forming units/g; M = microscopic lesions compatible with paratuberculosis present (granulomatous inflammation with acid-fast bacteria); B = bacteriologic isolation of Map and confirmation by polymerase chain reaction; dash (–) = no microscopic lesions compatible with paratuberculosis and no bacteriologic isolation of Map.

^b Euthanized 390 days after inoculation due to handling-related injury.

^c Euthanized 15 days after inoculation due to handling-related injury.

^d LN = lymph node.

levels in deer 504 by 286 days after inoculation. In contrast, using the commercial ELISA (Fig. 5), antibody responses were seen in deer 503 and 504 only, where antibody titers persisted in deer 503 to the end of the study, but declined in deer 504 after peaking 226 days after inoculation.

DISCUSSION

In spite of the low number of animals used in the current study, the results show that oral inoculation of 9-day-old white-tailed deer with 1.87×10^{10} CFU of Map results in clinical disease (soft to diarrhetic feces) as early as 146 days after inoculation, intermittent fecal shedding between

28 and 595 days after inoculation, and development of microscopic lesions consistent with paratuberculosis. Either cell-mediated or humoral immune responses to Map-related antigens were observed in all three experimentally inoculated deer surviving beyond 15 days after inoculation.

Clinical signs exhibited in the current study were similar to those described for naturally infected white-tailed deer (Libke and Walton, 1975). Clinical signs observed also were identical to those described in another report of experimental paratuberculosis in white-tailed deer (Williams, 2001), that is, loss of body condition, poor hair coat, and diarrhea. Soft to diarrhetic feces were noted in the current study

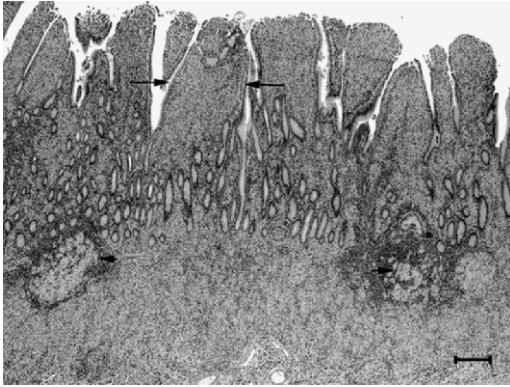


FIGURE 2. Section of ileum from deer 503, 658 days after oral inoculation with 1.87×10^{10} colony-forming units of *Mycobacterium avium* subsp. *paratuberculosis*. Note granulomatous infiltrations that expand the lamina propria (between long arrows) and invade submucosal lymphoid tissue (short arrows). H&E stain.

146 days (ca. 5 mo) to 505 days (ca. 17 mo) after inoculation. The few reported natural cases of clinical paratuberculosis in white-tailed deer involved animals 5 mo, 1.5 yr, and 4 yr of age (Libke and Walton, 1975; Chiodini and Van Kruinigen, 1983). It has generally been accepted that paratuberculosis in deer occurs at an age younger than that generally seen in cattle, where clinical disease is not seen until 2 to 10 yr of age

(Whitlock and Buergelt, 1996). In red deer, two clinical syndromes have been described previously (Mackintosh et al., 2004); sporadic disease in mixed ages of deer, characterized by low morbidity and high mortality, and severe outbreaks in 8–15-mo-old deer characterized by high morbidity (up to 20%) and high mortality. It is postulated that this latter syndrome in young red deer is the result of high challenge doses at a very young age. The paucity of naturally occurring clinical cases in white-tailed deer make conclusions regarding age of onset of clinical signs or the descriptions of different clinical syndromes difficult. In the current case, similar to cattle paratuberculosis, neonatal infection was followed by a subclinical period before clinical signs were evident. However, the subclinical period in the current study ranged from 5 to 17 mo, in contrast to cattle where clinical signs are rarely seen before 24 mo of age (Chiodini et al., 1984; Whitlock and Buergelt, 1996).

In cattle, shedding of Map can occur at any stage of the disease; however, Map is rarely detected before 24 mo of age (Chiodini, 1996). In contrast, deer in the current study shed high number of Map beginning 28 days after inoculation. This

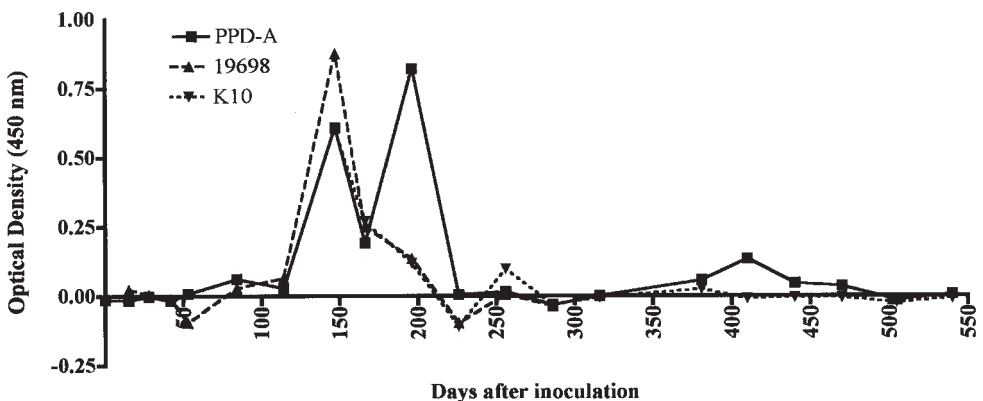


FIGURE 3. Interferon- γ responses of peripheral blood mononuclear cells from deer 503 after incubation with whole cell sonicates of *Mycobacterium avium* subsp. *paratuberculosis* (Map) strain K10, Map strain 19698, or *M. avium* purified protein derivative (PPD) (PPDa). Data represents optical density (450 nm) of antigen minus nil. Days represent days relative to oral inoculation with 1.87×10^{10} colony-forming units of Map (day 0).

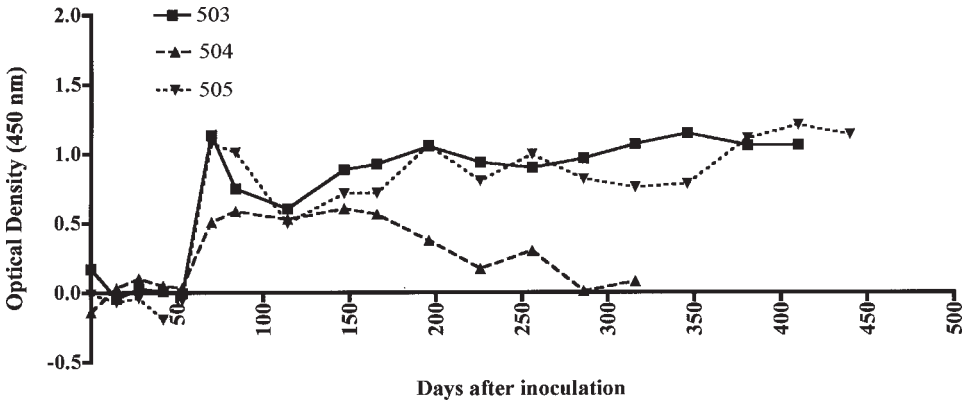


FIGURE 4. Serum antibody response of deer orally inoculated with 1.87×10^{10} colony-forming units of Map to lipoarabinomannan-enriched antigen. Days represent days relative to inoculation (day 0). Data are presented as Δ optical density (OD) (450 nm) calculated by subtracting the mean OD readings for wells receiving coating buffer alone (two replicates) from the mean OD readings for antigen-coated wells (two replicates) receiving the same serum sample.

difference may be due to the experimental nature of the inoculation, the high inoculum dosage, or to host species differences. The dose of Map administered to white-tailed deer in the current study would be characterized as high compared with previous studies of experimental infection of red deer (O'Brien et al., 2006) and cattle (Sweeney et al. 1992, 2006; Waters et al., 2003). Comparison of the dose used in the current study to that which deer are generally exposed during

natural infection is difficult, because natural infection likely involves highly variable degrees of repeated exposure; however, $>10^9$ CFU/g has been documented in feces from clinically affected sheep (Whittington et al., 2000), and doses as high as 10^8 CFU have been described as representative of natural infection (Reddacliff and Whittington, 2003).

The system proposed in the current study is unique in that shedding of Map has not been seen in other studies of

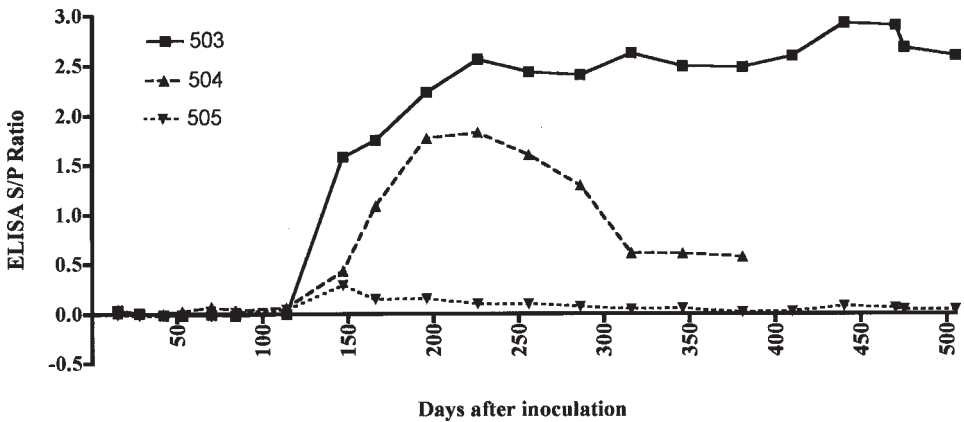


FIGURE 5. Serum antibody response of deer orally inoculated with 1.87×10^{10} colony-forming units of *Mycobacterium avium* subsp. *paratuberculosis* (Map) to Map antigens using a commercial enzyme-linked immunosorbent assay. Time is presented as days relative to inoculation (day 0). Data represent sample to positive (S/P) ratios of test samples (sample-negative control)/(positive control-negative control).

experimental infection of white-tailed deer (Williams et al., 1983a). This difference may be due to age at inoculation (5 mo vs. 9 days), duration of study (12 mo vs. 658 days or approximately 22 mo), source of inoculum (Bighorn sheep vs. bovine) or dose of inoculum. Source of inoculum can have a profound effect on virulence in a given host species. Susceptibility of red deer to bovine strains of Map has been shown to be greater than susceptibility to sheep strains (O'Brien et al., 2006). Recovery of Map from feces during the first 5 to 7 days after inoculation is likely due to passive shedding through the gastrointestinal tract, and it does not represent true shedding of Map. However, Map was regularly isolated from 147 days after inoculation through the termination of the study from both deer exhibiting clinical signs. Passive shedding of Map persisting 2 to 7 days after inoculation has been documented previously in orally inoculated adult cows (Sweeney et al., 1992), sheep (Reddacliff and Whittington, 2003), and neonatal calves (Sweeney et al., 2006).

Similar to other reported experimental and natural cases of paratuberculosis in white-tailed deer and red deer, marked thickening of the distal small intestine was not evident in the current cases of experimental paratuberculosis in white-tailed deer (Libke and Walton, 1975; Chiodini and Van Kruinigen, 1983; Mackintosh et al., 2004). Granulomatous inflammation with multifocal areas of necrosis was common in the current cases as well as other reported cases of paratuberculosis in deer (Williams, 2001). Necrosis and mineralization also have been described in enteric lesions of sheep orally inoculated with Map (Kluge et al., 1968); however, necrosis is uncommon in lesions of cattle with paratuberculosis (Buergelt et al., 1978). Cholesterol clefts as seen in the jejunal lymph node of deer 505 are not commonly described in microscopic lesions of paratuberculosis; however, cholesterol clefts have been reported in

mouse lungs after experimental infection with *Mycobacterium tuberculosis* (Shimono et al., 2003). The significance of cholesterol clefts within granulomas in the current study is uncertain.

Isolation of Map in low-to-moderate numbers from the brains of both deer 503 and 505 is curious. Using PCR, Map DNA was detected in blood from clinical cattle (Buergelt et al., 2004, 2006), suggesting a hematogenous phase in bovine paratuberculosis. Moreover, Map has been isolated and detected by PCR from brain and other tissues of fetuses examined from dams with clinical paratuberculosis, further supporting a hematogenous phase (Sweeney et al., 1992; Buergelt et al., 2006). It is likely that Map in the brain, as well as kidney, spleen, and lung, of deer in the current study is the result of a similar hematogenous phase.

Although noninoculated control animals were not available for comparison, experimental inoculation of white-tailed deer resulted in humoral or cell-mediated immune responses to Map antigens compared with preinoculation baseline values. Enzyme-linked immunosorbent assay has been used previously to diagnose paratuberculosis in white-tailed deer (Shulaw et al., 1986). Unfortunately, in previous studies, culture and histopathologic samples were not obtained to confirm infection; therefore, the accuracy of the ELISA is unclear (Shulaw et al., 1986). Previous studies in cattle report that the progression of paratuberculosis is associated with a decrease in cell-mediated immunity and an increase in antibody response. Similarly, in the current study, antibody responses, as measured by the commercial ELISA, rose between 50 and 100 days after inoculation, and they remained elevated in deer 503. At the same time, IFN- γ levels similarly rose, but then they fell to negligible levels by 200 days after inoculation. Recent reports have demonstrated that there may be no uniform pattern associated with antibody responses during disease progression but

rather that the response is highly dependent on the antigens and antibody isotypes examined (Koets et al., 2001; Waters et al., 2003). Similar to previous findings in experimentally infected cattle antibody responses were evident 50 to 150 days after inoculation, depending on the assay (Waters et al., 2003). Experimentally infected calves developed antibody responses as early as 134 days after inoculation, measurable by a similar LAM-enriched ELISA to that used in the current study. Interestingly, the commercial ELISA used in current study did not detect antibodies in experimentally infected calves (Waters et al., 2003). In the current study, the commercial ELISA demonstrated an antibody response in two of three deer beginning 150 days after inoculation. Deer 505 did not develop an antibody response as measured by the commercial ELISA; however, an antibody response was noted using the LAM-enriched ELISA. This inconsistency is likely due to the different nature of the antigens used in the different assays.

Lack of IFN- γ responses to Map by deer 504 and 505 suggests a lack of cell-mediated response to Map-related antigens. However, lack of response to PWM by deer 504 suggests either an inability of peripheral blood mononuclear cells (PBMCs) from that animal to respond to mitogen or a lack of ability of the Cervigam assay to measure IFN- γ from this particular deer. Findings (Waters, unpubl. data) suggest that up to 40% of white-tailed deer PBMCs do not respond to PWM as measured by the Cervigam assay. It has not been determined whether this is due to genetic differences between animals or to a lack of the anti-IFN- γ antibody used in the Cervigam to recognize IFN- γ from all white-tailed deer.

Housing and handling of white-tailed deer in biocontainment present several challenges not generally encountered when working with domestic ruminants. Even after hand feeding of fawns as in the current study, handling of animals to

obtain blood or feces was met with considerable resistance by the animal posing some degree of risk of injury to the animal. Use of white-tailed deer in any research involving long-term housing in biocontainment requires that probable animal losses be considered in experimental design planning.

White-tailed deer are the most numerous and widespread free-ranging ungulate in North America. The prevalence of paratuberculosis in free-ranging white-tailed deer is unknown, but it is presumed to be low (Raizman et al., 2005); however, sampling of deer feces around dairy farms has identified feces containing Map (Raizman et al., 2005). Serologic surveys of free-ranging white-tailed deer have been hindered by the lack of an adequate diagnostic assay (Davidson et al., 2004). With increased interest in diseases at the interface of domestic livestock and wildlife as well as the expansion of the deer farming industry in the United States, animal model systems, such as that described in the current study, will become increasingly important to investigate disease pathogenesis, diagnosis, and interspecies transmission of agents such as Map that serve as pathogens to both domestic and wild ruminants.

ACKNOWLEDGMENTS

The authors acknowledge the excellent technical assistance of T. Tatum, T. McNunn, P. Lasley, S. Zimmerman, D. Orcutt, B. Lyon, R. Renshaw, T. Duiitt, J. Hansen, D. Ewing, and J. Kent.

LITERATURE CITED

- BEGARA-McGORUM, I., L. A. WILDBLOOD, C. J. CLARKE, K. M. CONNOR, K. STEVENSON, C. J. MCINNES, J. M. SHARP, AND D. G. JONES. 1998. Early immunopathological events in experimental ovine paratuberculosis. *Veterinary Immunology Immunopathology* 63: 265–287.
- BUERGELT, C. D., C. HALL, K. McENTEE, AND J. R. DUNCAN. 1978. Pathological evaluation of paratuberculosis in naturally infected cattle. *Veterinary Pathology* 15: 196–207.
- , A. W. LAYTON, P. E. GINN, M. TAYLOR, J. M. KING, P. L. HABECKER, E. MAULDIN, R. WHIT-

- LOCK, C. ROSSITER, AND M. T. COLLINS. 2000. The pathology of spontaneous paratuberculosis in the North American bison (*Bison bison*). *Veterinary Pathology* 37: 428–438.
- , G. A. DONOVAN, AND J. E. WILLIAMS. 2004. Identification of *Mycobacterium avium* subspecies *paratuberculosis* by polymerase chain reaction in blood and semen of a bull with clinical paratuberculosis. *International Journal of Applied Veterinary Research* 2: 130–134.
- , E. WILLIAMS, G. R. G. MONIF, P. PINEDO, AND J. H. DECKER. 2006. Nested polymerase chain reaction and prenatal detection of *Mycobacterium avium* subspecies *paratuberculosis* (Map) in bovine allantoic fluid and fetuses. *International Journal of Applied Veterinary Research* 4: 232–238.
- CHIODINI, R. J. 1996. Immunology: Resistance to paratuberculosis. In *Veterinary clinics of North America: Food animal practice. Paratuberculosis (Johne's disease)*, R. W. Sweeney (ed.), W. B. Saunders Company, Philadelphia, pp. 313–343.
- , AND H. J. VAN KRUIJNINGEN. 1983. Eastern white-tailed deer as a reservoir of ruminant paratuberculosis. *Journal of the American Veterinary Medical Association* 182: 168–169.
- , AND R. S. MERKAL. 1984. Ruminant paratuberculosis (Johne's disease): The current status and future prospects. *Cornell Veterinarian* 74: 218–262.
- DAVIDSON, W. R., E. J. B. MANNING, AND V. F. NETTLES. 2004. Culture and serologic survey for *Mycobacterium avium* subsp. *paratuberculosis* infection among southeastern white-tailed deer (*Odocoileus virginianus*). *Journal of Wildlife Diseases* 40: 301–306.
- DELISLE, G. W., G. F. YATES, AND R. H. MONTGOMERY. 2003. The emergence of *Mycobacterium paratuberculosis* in farmed deer in New Zealand—A review of 619 cases. *New Zealand Veterinary Journal* 51: 58–62.
- HATTEL, A. L., D. P. SHAW, B. C. LOVE, D. C. WAGNER, T. R. DRAKE, AND J. W. BROOKS. 2004. A retrospective study of mortality in Pennsylvania captive white-tailed deer (*Odocoileus virginianus*): 2000–2003. *Journal of Veterinary Diagnostic Investigation* 16: 515–521.
- JESSUP, D. A., B. ABBAS, AND D. BEHYMER. 1981. Paratuberculosis in tule elk in California. *Journal of the American Veterinary Medical Association* 179: 1252–1254.
- KLUGE, J. P., R. S. MERKAL, W. S. MONLUX, A. B. LARSEN, K. E. KOPECKY, F. K. RAMSEY, AND R. P. LEHMANN. 1968. Experimental paratuberculosis in sheep after oral, intratracheal or intravenous inoculation: Lesions and demonstration of etiologic agent. *American Journal of Veterinary Research* 29: 953–962.
- KOETS, A. P., V. P. M. G. RUTTEN, M. DE BOER, D. BAKKER, P. VALENTINE-WEIGAND, AND W. VANDEN. 2001. Differential changes in heat shock protein-, lipoarabinomannan-, and purified protein derivative-specific immunoglobulin G1 and G2 isotype responses during bovine *Mycobacterium avium* subsp. *paratuberculosis* infection. *Infection and Immunity* 69: 1492–1498.
- LI, L., J. P. BANNANTINE, Q. ZHANG, A. AMONSIN, B. J. MAY, D. ALT, N. BANERJI, S. KANJILAL, AND V. KAPUR. 2005. The complete genome sequence of *Mycobacterium avium* subspecies *paratuberculosis*. *Proceedings of the National Academy of Sciences USA* 102: 12344–12349.
- LIBKE, K. G., AND A. M. WALTON. 1975. Presumptive paratuberculosis in a Virginia white-tailed deer. *Journal of Wildlife Diseases* 11: 552–553.
- MACKINTOSH, C. G., G. W. DE LISLE, D. M. COLLINS, AND J. F. T. GRIFFIN. 2004. Mycobacterial diseases of deer. *New Zealand Veterinary Journal* 52: 163–174.
- O'BRIEN, R., C. G. MACKINTOSH, D. BAKKER, M. KOPECKA, I. PAVLIK, AND J. F. T. GRIFFIN. 2006. Immunological and molecular characterization of susceptibility in relationship to bacterial strain differences in *Mycobacterium avium* subsp. *paratuberculosis* infection in red deer (*Cervus elaphus*). *Infection and Immunity* 74: 3530–3537.
- PALMER, M. V., W. R. WATERS, D. L. WHIPPLE, R. E. SLAUGHTER, AND S. L. JONES. 2004. Evaluation of an in vitro blood-based assay to detect production of interferon- γ by *Mycobacterium bovis*-infected white-tailed deer (*Odocoileus virginianus*). *Journal of Veterinary Diagnostic Investigation* 16: 17–21.
- QUIST, C. F., V. F. NETTLES, E. J. B. MANNING, D. G. HALL, J. K. GAYDON, T. J. WILMERS, AND R. R. LOPEZ. 2002. Paratuberculosis in Key deer (*Odocoileus virginianus clavium*). *Journal of Wildlife Diseases* 38: 729–737.
- RAIZMAN, E. A., S. J. WELLS, P. A. JORDAN, G. D. DELGIUDICE, AND R. R. BEY. 2005. *Mycobacterium avium* subsp. *paratuberculosis* from free-ranging deer and rabbits surrounding Minnesota dairy farms. *Canadian Journal of Veterinary Research* 69: 32–38.
- REDDACLIFF, L. A., AND R. J. WHITTINGTON. 2003. Experimental infection of weaner sheep with S strain *Mycobacterium avium* subsp. *paratuberculosis*. *Veterinary Microbiology* 96: 247–258.
- SHIMONO, N., L. MORICI, N. CASALI, S. CANTRELL, B. SIDERS, S. EHRT, AND L. W. RILEY. 2003. Hypervirulent mutant of *Mycobacterium tuberculosis* resulting from disruption of the *mce1* operon. *Proceedings of the National Academy of Sciences USA* 100: 15918–15923.
- SHULAW, W. P., J. C. GORDON, S. BECH-NIELSEN, C. I. PRETZMAN, AND G. F. HOFFSIS. 1986. Evidence of paratuberculosis in Ohio's white-tailed deer, as determined by an enzyme-linked immunosor-

- bent assay. *American Journal of Veterinary Research* 47: 2539–2542.
- STABEL, J. R. 1997. An improved method for cultivation of *Mycobacterium paratuberculosis* from bovine fecal samples and comparison to three other methods. *Journal of Veterinary Diagnostic Investigation* 9: 375–380.
- , M. V. PALMER, AND R. H. WHITLOCK. 2003. Immune responses after oral inoculation of weanling bison or beef calves with a bison or cattle isolate of *Mycobacterium avium* subsp. *paratuberculosis*. *Journal of Wildlife Diseases* 39: 545–55.
- STORSET, A. K., H. J. HASVOLD, M. VALHEIM, H. BRUNHANSEN, G. BERNSTEN, S. K. WHIST, B. DJONNE, C. M. PRESS, G. HOLSTAD, AND H. J. LARSEN. 2001. Subclinical paratuberculosis in goats following experimental infection: An immunological and microbiological study. *Veterinary Immunology and Immunopathology* 80: 271–287.
- SWEENEY, R. W., R. H. WHITLOCK, A. N. HAMIR, A. E. ROSENBERGER, AND S. A. HERR. 1992. Isolation of *Mycobacterium paratuberculosis* after oral inoculation in uninfected cattle. *American Journal of Veterinary Research* 53: 1312–1314.
- , ———, AND A. E. ROSENBERGER. 1992. *Mycobacterium paratuberculosis* isolated from fetuses of infected cows not manifesting signs of the disease. *American Journal of Veterinary Research* 53: 477–480.
- , J. UZONNA, R. H. WHITLOCK, P. L. HABECKER, P. CHILTON, AND P. SCOTT. 2006. Tissue predilection sites and effect of dose on *Mycobacterium avium* subsp. *paratuberculosis* organism recovery in a short-term bovine experimental oral infection model. *Research in Veterinary Science* 80: 253–259.
- WATERS, W. R., M. V. PALMER, AND D. L. WHIPPLE. 2002. *Mycobacterium bovis*-infected white-tailed deer (*Odocoileus virginianus*): Detection of immunoglobulin specific to crude mycobacterial antigens by ELISA. *Journal of Veterinary Diagnostic Investigation* 14: 470–475.
- , J. M. MILLER, M. V. PALMER, J. R. STABEL, D. E. JONES, K. A. KOINSTINEN, E. M. STEADHAM, M. J. HAMILTON, W. C. DAVIS, AND J. P. BANNANTINE. 2003. Early induction of humoral and cellular immune responses during experimental *Mycobacterium avium* subsp. *paratuberculosis* infection of calves. *Infection and Immunity* 71: 5130–5138.
- WHITLOCK, R. H., AND C. BUERGELT. 1996. Preclinical and clinical manifestations of paratuberculosis (including pathology). Paratuberculosis (Johne's disease) *In Veterinary clinics of North America: Food animal practice*, R. W. Sweeney (ed.). W. B. Saunders Company, Philadelphia, pp. 345–355.
- WHITTINGTON, R. J., L. A. REDDAKLIFF, I. MARSH, S. MCALLISTER, AND V. SAUNDERS. 2000. Temporal patterns and quantification of excretion of *Mycobacterium avium* subsp. *paratuberculosis* in sheep with Johne's disease. *Australian Veterinary Journal* 78: 34–37.
- WILLIAMS, E. S. 2001. Paratuberculosis and other mycobacterial diseases. *In Infectious diseases of wild mammals*, 3rd Edition, E. S. Williams and I. K. Barker (eds.). Iowa State University Press, Ames, pp. 362–371.
- , S. P. SNYDER, AND K. L. MARTIN. 1983a. Experimental infection of some North American wild ruminants and domestic sheep with *Mycobacterium paratuberculosis*: Clinical and bacteriological findings. *Journal of Wildlife Diseases* 19: 185–191.
- , ———, AND ———. 1983b. Pathology of spontaneous and experimental infection of North American ruminants with *Mycobacterium paratuberculosis*. *Veterinary Pathology* 20: 274–291.
- , J. C. DEMARTINI, AND S. P. SNYDER. 1985. Lymphocyte blastogenesis, complement fixation, and fecal culture as diagnostic tests for paratuberculosis in North American wild ruminants and domestic sheep. *American Journal of Veterinary Research* 46: 2317–2321.

Received for publication 23 October 2006.