

Feline Leukemia Virus in a Captive Bobcat

Jonathan M. Sleeman,^{1,4} Jennifer M. Keane,² Jeremy S. Johnson,² Rebecca J. Brown,³ Sue Vande Woude²

¹ Department of Clinical Sciences, and ² Department of Pathology, College of Veterinary Medicine and Biomedical Sciences, Colorado State University, Fort Collins, Colorado 80523, USA; ³ Moore Lane Veterinary Hospital, 50 Moore Lane, Billings, Montana 59101, USA; ⁴ Corresponding author (e-mail: js546@umail.umd.edu).

ABSTRACT: An 11-mo-old captive-bred male neutered bobcat (*Felis rufus*) presented with lethargy, anorexia, leukopenia, neutropenia, lymphopenia, and nonregenerative anemia. The animal was diagnosed as feline leukemia virus (FeLV) positive by immunofluorescent antibody and enzyme-linked immunosorbant assay (ELISA) testing. It died despite supportive care. Pathologic examination revealed multifocal non-suppurative encephalitis, diffuse interstitial pneumonia, multifocal hepatocellular necrosis, non-suppurative peritonitis, and lymphoid depletion. FeLV was isolated from peripheral blood mononuclear cells, bone marrow, spleen, and lymph node. FeLV-specific *gag* sequences were amplified by DNA polymerase chain reaction (PCR) and aligned with known domestic cat FeLVs. The source of the virus was speculated to be a domestic cat that was a surrogate nurse. Case reports of FeLV in nondomestic felids are few, and FeLV does not appear to be enzootic in wild felids, except European wildcats (*Felis silvestris*) in France and Scotland. Introduction of FeLV into free-living and captive nondomestic felid populations could have serious consequences for their health and survival. Measures to prevent the introduction of this virus to nondomestic felids are warranted.

Key words: Bobcat, case report, feline leukemia virus, *Felis rufus*.

The occurrence of lentiviruses closely related to feline immunodeficiency virus (FIV) has been reported in a variety of nondomestic felids worldwide (Olmstead et al., 1992). In contrast, reports of feline leukemia virus (FeLV) infection are few and are all single case reports (Rasheed and Gardner, 1981; Meric, 1984; Briggs and Ott, 1986; Citino, 1986; Jessup et al., 1993). This report describes the clinical, pathologic and virologic findings of FeLV infection in a bobcat (*Felis rufus*), and discusses the implications for free-living and captive nondomestic felids.

An 11-mo-old male neutered bobcat presented to the Zoological Medicine Ser-

vice, (Colorado State University, Fort Collins, Colorado, USA) with a 9 mo history of lethargy, partial anorexia, and marked anemia. These clinical signs first manifested at 2 mo of age, at which time it was diagnosed as FeLV positive by immunofluorescent antibody and enzyme-linked immunosorbant assay (ELISA) antigen testing. Treatment consisted of a variety of antibiotics, interferon, and erythropoietin. Its condition waxed and waned over the next 9 mo; however, recently its condition had deteriorated. The animal was captive-raised and removed from its mother at 48 hr to be nursed by a domestic cat. It was vaccinated for feline panleukopenia, calicivirus, and rhinotracheitis virus (FEL-O-VAX PCT killed virus vaccine, Fort Dodge Animal Health, Fort Dodge, Iowa, USA) at 4, 8, and 12 wks of age, but had not been vaccinated for FeLV.

On physical examination the bobcat was found to be thin, lethargic and slightly depressed. There were increased inspiratory sounds on auscultation of the thorax, and the mucous membranes were pale. The animal was considered mildly dehydrated. The total white blood cell count was $2.8 \times 10^3 \mu\text{l}$; neutrophils were $1.1 \times 10^3 \mu\text{l}$, and lymphocytes were $1.3 \times 10^3 \mu\text{l}$ indicating leukopenia, neutropenia and lymphopenia when compared to published reference ranges (Fuller et al., 1985; Kocan et al., 1985; Heidt et al., 1988). In addition, there was a marked macrocytic nonregenerative anemia (PCV was 11%; MCV was 77, and reticulocytes were 0.5%) (Jain, 1986). The chemistry panel was unremarkable except for mild hypokalemia, and elevations of alanine aminotransferase (ALT) (498 IU/L) and aspartate aminotransferase (AST) (509 IU/L) suggesting liver damage. Immunofluorescent antibody and ELISA

antigen testing were repeated and confirmed the FeLV positive status. Western blot analyses for FIV and cougar lentivirus antibodies were performed as described by Vande Woude et al. (1997) and were found to be negative. In addition, serologies for *Toxoplasma gondii* IgG and IgM antibodies and feline infectious peritonitis (FIP) antibodies also were negative. Thoracic and abdominal radiographs showed a severe peribronchial and interstitial pattern throughout all the lung lobes, and mild hepatomegaly. Tracheal washing revealed suppurative inflammation. A bone marrow aspirate of the iliac crest revealed myelodysplasia with erythroid predominance (Jain et al., 1991). The samples were of poor quality with hemodilution and no appreciable particles. The erythroid series was shifted to the left with mostly immature forms present. There was also dysynchrony of maturation in the erythroid precursors with early hemoglobinization, occasional binucleated metarubricytes, megakoblasts, and abnormal mitotic figures, consistent with FeLV.

Despite supportive care, the animal died 3 days after presentation. A gross postmortem examination revealed generalized pallor to all tissues and blood with decreased viscosity that resisted clotting, suggestive of anemia. There was no evidence of blood loss or a coagulopathy based on the lack of free blood in various body cavities and intestinal lumens. The retropharyngeal, submandibular, popliteal and mesenteric lymph nodes were approximately 70% normal size, and on cut section were mottled red and tan with a poorly defined corticomedullary junction. The lungs were mottled purple, red and pink, and had a rubbery texture. Cut section exuded moderate amounts of serosanguinous fluid.

Sections from multiple organs were collected and fixed in 10% formalin then sectioned at 4–5 μm and stained with hematoxylin and eosin. Histologically, sections of lung had thickened alveolar walls containing increased numbers of neutrophils

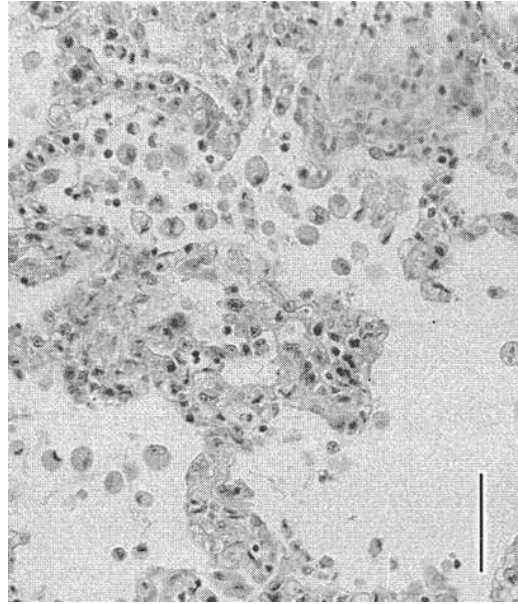


FIGURE 1. Section of lung from a bobcat with FeLV infection showing thickened alveolar walls containing mixed leukocytes with macrophages and fibrin in alveoli. H&E. Bar = 100 μm .

and macrophages with fewer lymphocytes and plasma cells and occasional necrotic cells (Fig. 1). Epithelial macrophages were seen in modest numbers in alveoli with little fibrin. Subcortical white matter tracts and cortical gray matter of the cerebrum had multifocal accumulations of astrocytes and microglia (Fig. 2). The cerebellum contained a focal area of hemorrhage, gliosis, and gitter cells in white matter tracts. Random multifocal areas of necrosis were scattered throughout the liver with increased lymphocytes and plasma cells around portal triads (Fig. 3). Bone marrow sections had adequate cellularity and a heterogenous cellular population. There were decreased numbers of mature myeloid cells in the face of adequate to increased numbers of erythroid cells. The myeloid pyramid was left shifted with decreased numbers of mature myeloid cells. Occasional megaloblasts were seen. Tissue from the ileocecal junction had perivascular inflammation and focal myofiber degeneration in the outer longitudinal muscle. An associated lymph node had multi-

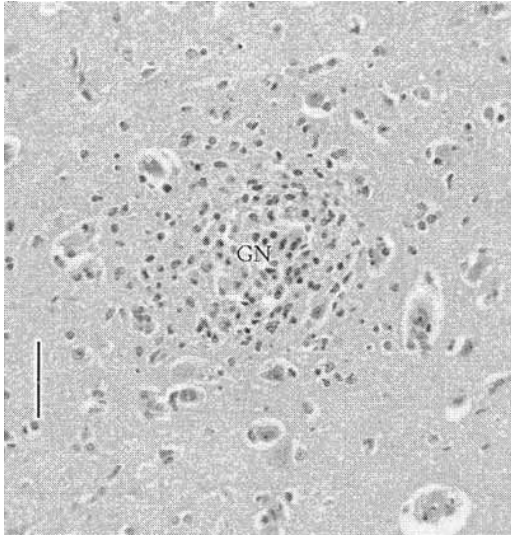


FIGURE 2. Section of cerebrum from a bobcat with FeLV infection with a single glial nodule in cortical gray matter (GN). H&E. Bar = 100 μ m.

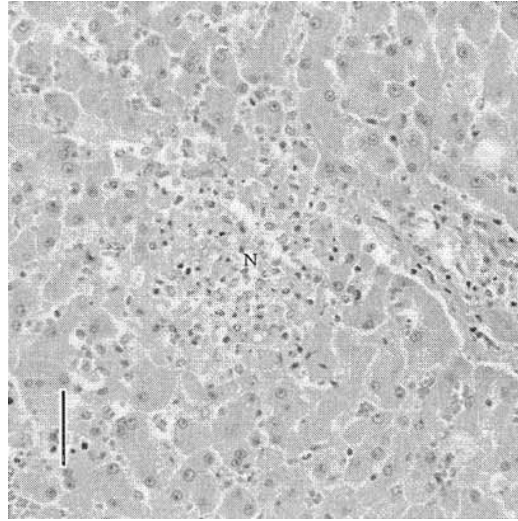


FIGURE 3. Section of liver from a bobcat with FeLV infection showing a single necrotic foci (N), and karyorrhexis with little inflammation. H&E. Bar = 100 μ m.

focal areas of cortical lymphoid depletion with increased macrophages and neutrophils. Spleen, liver, and lymph node sections lacked extramedullary hematopoiesis.

Feline T lymphocyte immunophenotype labeling was performed on antemortem blood with monoclonal antibodies recognizing feline CD4 and CD8 T cell epitopes (O'Reilly and Hoover, 1993) as described by Dean et al. (1991). Lymphocyte subset percentages were analyzed with a Coulter EPICS Profile II flow cytometer. Total CD4+ and CD8+ cell numbers were calculated by applying subset percentages to total lymphocytes as determined by complete blood count and revealed that the animal had 200 CD4+ lymphocytes/ μ l and 80 CD8+ cells/ μ l. Normal values measured in our laboratory for domestic cats are a CD4+/CD8+ ratio >2; >400 CD4+/ μ l and >100 CD8+/ μ l.

Plasma and peripheral blood mononuclear cells (PBMC) were isolated from anticoagulated blood using standard methodologies (Quackenbush et al., 1991). Frozen spleen, bone marrow and peripheral lymph node collected at necropsy were passed through a sieve and cells counted. One million viable PBMC, 50 μ l of plas-

ma, and five million nonviable spleen, bone marrow, or lymph node cells were cultured in 24 well plates with an equivalent number of naive feline PBMC or crandell feline kidney cells. Supernatant was collected biweekly for 3 wk and tested for presence of virus using an FeLV-specific antigen capture ELISA (Zeidner et al., 1990). All virus cultures were strongly ELISA positive by day 7.

DNA was extracted from spleen, bone marrow, lymph node and PBMC using a commercial extraction assay (QIAamp blood kit; QIAGEN, Inc., Valencia, California, USA) and quantified at 260 nm by spectrophotometry. Nested polymerase chain reaction (PCR) was performed using two primer pairs from a conserved region in the *gag* gene that flank and amplify 747 and 147 base pair gene products in the first and second rounds, respectively. Second round reactions were employed to enhance specificity and sensitivity of the PCR reaction. The primer sequences used were: 5'-3': first round- CCCTCCGCCCTCTT/CCTGCCCTGGGTCCTC, and second round- GGCGAAGAAAGGCAAAGGGTC/TGGCGATAAAGGCGTAGGTG. Hot start

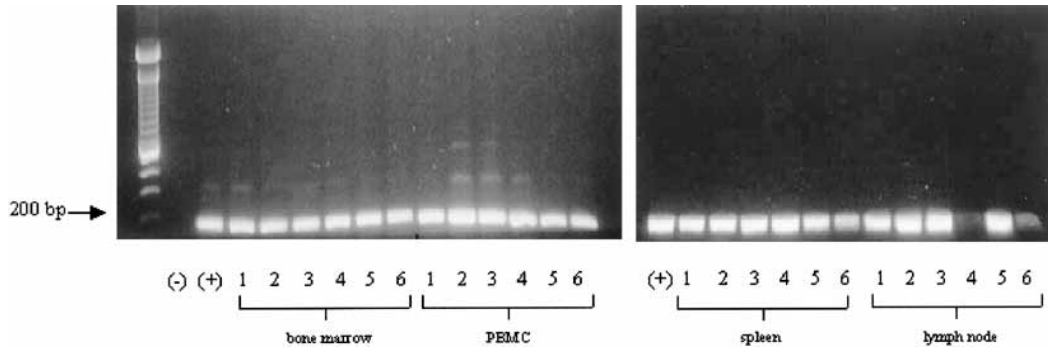


FIGURE 4. Second round DNA PCR products for FeLV *gag* from bone marrow, PBMC, spleen, and lymph node of a bobcat. bp = base pairs; (-) = FeLV negative PBMC control; (+) = FeLV positive PBMC control; 1 = 1 μ g DNA used in first round; 2 = 0.1 μ g DNA; 3 = 1×10^{-2} μ g DNA; 4 = 1×10^{-3} μ g DNA; 5 = 1×10^{-4} μ g DNA; 6 = 1×10^{-5} μ g DNA.

PCR was performed using Hot Start 100 tubes (Molecular BioProducts, San Diego, California, USA), $1 \times$ PCR Buffer, 2 mM MgCl₂, 300 μ M concentration of each dNTP, 1 μ M concentration of each primer, 5 units of Taq DNA Polymerase (Sigma Chemical Co., St. Louis, Missouri, USA), and DNA as described below for 34 cycles of 1 min each at 94, 58, and 72 C. Six log serial dilutions of 1 g of DNA were added to the first round reactions, and 1 μ l of a 1:10 dilution of first round product was used in each second round reaction. Amplification products were electrophoresed at 105 V for 60 min through 1.5% agarose gels stained with ethidium bromide or Gelstar, (FMC BioProducts, Rockland, Maine, USA) and visualized under UV transillumination. Amplification products from first and second round were sequenced using a Perkin Elmer ABI 377 Automated DNA Sequencer (Macromolecular Resources, Department of Biochemistry, Colorado State University, Fort Collins, Colorado, USA) and the appropriate FeLV primer pair. Sequences were analyzed on NCBI GenBank database using BLAST software (<http://www.ncbi.nlm.nih.gov/BLAST/>).

An appropriately sized second round PCR fragment was amplified from all dilutions (0.01 ng to 1 μ g) of spleen, bone marrow and PBMC DNA; PCR of lymph node detected virus to at least the 0.1 ng dilution (Fig. 4). This correlates to 1 copy

of viral genome per 1–10 cells. A 553 base pair segment of the first round amplicon was aligned with the GenBank sequence database using GenBank BLAST sequence analysis (Accession number AF275797). A variety of FeLV A and B subgroup viruses aligned with 92 to 93% nucleotide homology. The entire inner fragment was also sequenced. It aligned with the same domestic cat FeLV sequences as the outer fragment with 94 to 96% nucleotide homology.

Significant histopathologic findings included moderate multifocal nonsuppurative encephalitis, moderate random hepatic necrosis, moderate diffuse interstitial pneumonia, and non-suppurative perivascular peritonitis. These findings are non-specific and may be secondary to immunosuppression resulting in viral, bacterial, or protozoal infections, or directly associated with FeLV (Cotter, 1976; Hoover and Mullins, 1991). Sections of liver, lung and brain were supportive of a concurrent bacterial infection and septicemia. Passive congestion and hemosiderin laden macrophages were not present in lung sections, and iron stains of lung tissue did not support heart failure secondary to anemia.

Perivascular inflammation in sections of tissue from the ileocecal junction was consistent with FIP. Feline coronavirus was considered a potential cause of histopathologic findings because of the vascular ori-

entation of lesions along the ileocecal junction. FIP antibody titer <1:10 was suggestive of a lack of exposure or an acute infection. The distribution and extent of histologic changes were more consistent with an established infection; however, FIP could not be definitively ruled out as a concurrent disease.

Bone marrow histopathology revealed increased cellularity as opposed to cytologic preparations (a reflection of sampling); histopathologic findings did not support erythroleukemia or aplastic anemia, but were consistent with myelodysplasia. Macrocytic nonregenerative anemia has been reported in feline leukemia virus-infected cats (Weiser and Kociba, 1983). The development of macrocytosis suggests that a regenerative response occurred and subsequently converted to a nonregenerative anemia. Weiser and Kociba (1983) hypothesized that the duration of erythroid regeneration before erythroid hypoplasia is short and that reticulocytosis is not detected due to sampling frequency. The lack of dysplastic erythroid precursors in the peripheral blood suggests that the bone marrow was adequately controlling the release of normal erythroid precursors by preventing dysplastic cells from entering the circulation.

Low absolute numbers of CD4+ and CD8+ lymphocytes were consistent with the lymphopenia. The CD4+/CD8+ ratio was appropriate. FeLV was readily cultured from peripheral blood, plasma, and frozen spleen, lymph node and bone marrow, indicating a high level of systemic infection that could be propagated in domestic cat origin cells. Sequence analysis showed a high level of homology between this FeLV isolate and others characterized from the domestic cat, supporting the hypothesis that infection occurred from exposure to domestic cat FeLV rather than being a novel nondomestic virus.

The clinical and pathologic findings were similar to those seen in domestic cats with FeLV infection (Nelson and Couto, 1998). FeLV was considered the primary

cause of disease in this animal because it was readily isolated from multiple tissues, and secondary infections such as FIV, FIP and toxoplasmosis were not detected by serologic analysis.

This and other case reports demonstrate that nondomestic felids are susceptible to infection with domestic cat FeLV, which should be considered a potential emerging disease in large cats (Kennedy-Stoskopf, 1999). In this case, the source is speculated to be the domestic cat that acted as a surrogate nurse, since it is known that queen to kitten transmission can occur in domestic cats (Lawler and Evans, 1997).

Serologic surveys of free-living mountain lions (*Felis concolor*) in California and Florida panthers (*Felis concolor*) indicate an absence of exposure to FeLV (Roelke et al., 1993; Paul-Murphy et al., 1994). In addition, a study by Osofsky et al. (1996) indicates that FeLV also is not enzootic in free-living African felids from Botswana. In contrast, in a survey of wildcats (*Felis silvestris*) from Scotland, 10% were positive for FeLV antigen which could have resulted from contact with domestic or feral domestic cats (Daniels et al., 1999). FeLV may have also been responsible for lymphadenopathy seen in one wildcat (McOrist et al., 1991). In addition, a survey of wildcats in France revealed a 23.7% prevalence of FeLV infection, and demonstrated a significant relationship between infection and poor body condition (Fromont et al., 2000). Further surveys to determine the FeLV status of free-living and captive nondomestic felids are warranted. FeLV-infected domestic/feral cats could potentially introduce this virus to populations of wild and captive felids. This would have devastating consequences for the health and survival of these populations. All attempts should be made to keep potentially infected domestic cats isolated from nondomestic felids, and the safety and efficacy of FeLV vaccination in nondomestic felids at risk for exposure should be more fully evaluated (Kennedy-Stoskopf, 1999).

We thank C. Hageman and B. Taylor for technical assistance, K. Keane for assistance with figure preparation, and E. Hoover for consultation, laboratory support and technical advice. This research was supported in part by PHS 5R29AI41871.

LITERATURE CITED

- BRIGGS, M. B., AND R. L. OTT. 1986. Feline leukemia virus infection in a captive cheetah and the clinical and antibody response of six captive cheetahs to vaccination with a subunit feline leukemia virus vaccine. *Journal of the American Veterinary Medical Association* 189: 1197-1199.
- CITINO, S. B. 1986. Transient FeLV viremia in a clouded leopard. *Journal of Zoo and Wildlife Medicine* 17: 5-7.
- COTTER, S. M. 1976. Feline leukemia virus induced disorders in the cat. *Veterinary Clinics of North America* 6: 367-378.
- DANIELS, M. J., M. C. GOLDBER, O. JARRETT, AND D. W. MACDONALD. 1999. Feline viruses in wildcats from Scotland. *Journal of Wildlife Diseases* 35: 121-124.
- DEAN, G. A., S. L. QUACKENBUSH, C. D. ACKLEY, M. D. COOPER, AND E. A. HOOVER. 1991. Flow cytometric analysis of T-lymphocyte subsets in cats. *Veterinary Immunology and Immunopathology* 28: 327-335.
- FROMONT, E., A. SAGER, F. LEGER, F. BOURGUEMESTRE, E. JOUQUELET, P. STAHL, D. PONTIER, AND M. ARTOIS. 2000. Prevalence and pathogenicity of retroviruses in wildcats in France. *Veterinary Record* 146: 317-319.
- FULLER, T. K., K. D. KERR, AND P. D. KARN. 1985. Hematology and serum chemistry of bobcats in north central Minnesota. *Journal of Wildlife Diseases* 21: 29-32.
- HEIDT, G. A., R. A. RUCKER, M. L. KENNEDY, AND M. E. BAEYENS. 1988. Hematology, intestinal parasites and selected disease antibodies from a population of bobcats (*Felis rufus*) in central Arkansas. *Journal of Wildlife Diseases* 24: 180-183.
- HOOVER, E. A., AND J. I. MULLINS. 1991. Feline leukemia virus infection and diseases. *Journal of the American Veterinary Medical Association* 199: 1287-1297.
- JAIN, N. C. 1986. Normal values in blood of laboratory, fur-bearing, and miscellaneous zoo, domestic, and wild animals. *In Veterinary hematology*, 4th Edition. Lea & Febiger, Philadelphia, Pennsylvania, 335 pp.
- , J. T. BLUE, C. B. GRINDEM, J. W. HARVEY, G. J. KOCIBA, J. D. KREHBIEL, K. S. LATIMER, R. E. RASKIN, M. A. THRALL, AND J. G. ZINKI. 1991. Proposed criteria for classification of acute myeloid leukemia in dogs and cats. *Journal of Veterinary Clinical Pathology* 20: 63-82.
- JESSUP, D. A., K. C. PETTAN, L. J. LOWENSTINE, AND N. C. PEDERSEN. 1993. Feline leukemia virus infection and renal spirochetosis in a free-ranging cougar (*Felis concolor*). *Journal of Zoo and Wildlife Medicine* 24: 73-79.
- KENNEDY-STOSKOPF, S. 1999. Emerging viral infections in large cats. *In Zoo and wild animal medicine*, M. E. Fowler and R. E. Miller (eds.). W. B. Saunders, Co., Philadelphia, Pennsylvania, pp. 401-410.
- KOCAN, A. A., E. F. BLOUIN, AND B. L. GLENN. 1985. Hematologic and serum chemical values for free-ranging bobcats, *Felis rufus* (Schreber), with reference to animals with natural infections of *Cytauxzoon felis*. *Journal of Wildlife Diseases* 21: 190-192.
- LAWLER, D. F., AND R. H. EVANS. 1997. Strategies for controlling viral infections in feline populations. *In Consultations in feline internal medicine*, 3rd Edition, J. R. August (ed.). W. B. Saunders, Co., Philadelphia, Pennsylvania, pp. 603-610.
- MCCORIST, S., R. BOID, T. W. JONES, N. EASTERBEE, A. L. HUBBARD, AND O. JARRETT. 1991. Some viral and protozoal diseases in the European wildcat (*Felis silvestris*). *Journal of Wildlife Diseases* 27: 693-696.
- MERIC, S. M. 1984. Suspected feline leukemia virus infection and pancytopenia in a western cougar. *Journal of the American Veterinary Medical Association* 185: 1390-1391.
- NELSON, R. W., AND C. G. COUTO. 1998. *Small animal internal medicine*. Mosby, Inc., St. Louis, Missouri, 1417 pp.
- OLMSTEAD, R. A., R. LANGLEY, M. E. ROELKE, R. M. GOEKEN, D. ADGER-JOHNSON, J. P. GOFF, J. P. ALBERT, C. PACKER, M. K. LAURENSEN, T. M. CARO, L. SCHEEPERS, D. E. WILDT, M. BUSH, J. S. MARTENSON, AND S. J. O'BRIEN. 1992. Worldwide prevalence of lentivirus infection in wild feline species: epidemiologic and phylogenetic aspects. *Journal of Virology* 66: 6008-6018.
- O'REILLY, K. L., AND E. A. HOOVER. 1993. Characterization of a panel of monoclonal antibodies specific for subsets to feline leukocytes. *In The second international feline retrovirus symposium*, W. A. Tompkins (ed.). North Carolina State University, Raleigh, North Carolina, p. 38.
- OSOFSKY, S. A., K. J. HIRSCH, E. E. ZUCKERMAN, AND W. D. HARDY. 1996. Feline lentivirus and feline oncovirus status of free-ranging lions (*Panthera leo*), leopards (*Panthera pardus*), and cheetahs (*Acinonyx jubatus*) in Botswana: A regional perspective. *Journal of Zoo and Wildlife Medicine* 27: 453-467.
- PAUL-MURPHY, J., T. WORK, D. HUNTER, E. MACFIE, AND D. FJELLINE. 1994. Serologic survey and serum biochemical reference ranges of the free-ranging mountain lion (*Felis concolor*) in California. *Journal of Wildlife Diseases* 30: 205-215.

- QUACKENBUSH, S. L., P. R. DONAHUE, G. A. DEAN, M. H. MYLES, C. D. ACKLEY, M. D. COOPER, J. I. MULLINS, AND E. A. HOOVER. 1991. Lymphocyte subset alterations and viral determinants of immunodeficiency disease induction by the feline leukemia virus FeLV-FAIDS. *Journal of Virology* 64: 5465–5474.
- RASHEED, S., AND M. B. GARDNER. 1981. Isolation of feline leukemia virus from a leopard cat cell line and search for retrovirus in wild Felidae. *Journal of National Cancer Institute* 67: 929–933.
- ROELKE, M. E., D. J. FORRESTER, E. R. JACOBSON, G. V. KOLLIAS, M. C. BARR, J. F. EVERMANN, AND E. G. PIRTLE. 1993. Seroprevalence of infectious disease agents in free-ranging Florida panthers (*Felis concolor coryi*). *Journal of Wildlife Diseases* 29: 36–49.
- VANDE WOUDE, S., S. J. O'BRIEN, K. LANGELIER, W. D. HARDY, J. P. SLATTERY, E. E. ZUCKERMAN, AND E. A. HOOVER. 1997. Growth of lion and puma lentiviruses in domestic cat cells and comparisons with FIV. *Virology* 233: 185–192.
- WEISER, M. G., AND G. J. KOCIBA. 1983. Erythrocyte macrocytosis in feline leukemia virus associated anemia. *Veterinary Pathology* 20: 687–697.
- ZEIDNER, N. S., L. M. ROSE, C. K. MATHIASON, M. H. MYLES, D. L. HILL, J. I. MULLINS, AND E. A. HOOVER. 1990. Zidovudine in combination with alpha interferon and interleukin-2 as prophylactic therapy for FeLV-induced immunodeficiency syndrome (FeLV-FAIDS). *Journal of Acquired Immune Deficiency Syndromes* 3: 787–796.

Received for publication 11 January 2000.