

Parasitic Enteritis in Superb Lyrebirds (*Menura novaehollandiae*)

Steven McOrist and Peter C. Scott, Veterinary Research Institute, Park Drive, Parkville, Victoria 3052, Australia

ABSTRACT: Ten free-living superb lyrebirds (*Menura novaehollandiae*) from forest habitat in southern Victoria, Australia were examined at necropsy over a 10 yr period. The acanthocephalan *Plagiorhynchus menurae* was identified in two lyrebirds from forest habitat in southern Victoria, Australia. There was necrotic enteritis in the duodenum associated with the acanthocephalans, with secondary bacterial involvement. The lesions probably resulted in the observed emaciation and debilitation of the birds. Probably the forest-floor habitat and insect diet of lyrebirds exposes them to these infections.

Key words: Superb lyrebirds, *Menura novaehollandiae*, *Plagiorhynchus menurae*, acanthocephalan, necrotic enteritis, case histories.

The superb lyrebird (*Menura novaehollandiae*) is a large ground bird inhabiting dense rain forest in southeastern Australia. Its diet consists of forest floor arthropods. Although the lyrebird is a national emblem, due to its particular song ability and the male's lyre-shaped tail feathering, little is known of its diseases. Clearing of habitat and predation by feral cats (*Felis domesticus*) is thought to have caused a decline in the number of these birds in recent years. They are territorial winter breeders, with one egg per clutch, laid in a large domed nest-mound. This report describes parasitic enteritis in these birds.

Over a 4 yr period two mature, male superb lyrebirds were found in woodland adjacent to dense eucalypt forest near Healesville, Victoria, Australia (37°40'S, 145°30'E). The birds were too weak to walk properly. The birds were emaciated but ate food that was offered. One bird exhibited respiratory distress. Both collapsed and died after several days in captivity despite supportive treatment and were taken to the Veterinary Research Institute (Parkville, Victoria 3052, Australia) for examination. At necropsy, there was necrosis of

the superficial mucosa of the duodenum, with 10 to 30, 0.5 cm to 2 cm long, acanthocephalans adherent to the necrotic mucosa. The intestinal lumen contained necrotic debris, a small amount of free blood and occasional cestodes of the genus *Choanotaenia*. In one bird, consolidation and edema of the lungs were evident. Eight other free-living lyrebirds examined at necropsy between 1978 and 1988 revealed no intestinal lesions or parasites.

The acanthocephalans were teased from the lesions, preserved in 70% glycerin-alcohol, and subsequently identified as *Plagiorhynchus menurae* (Johnston, 1912a, b). Representative specimens of the acanthocephalans and cestodes were deposited in the Australian Helminthological Collection (South Australian Museum, Adelaide, South Australia) as AHC numbers 17976 and 17977, respectively.

Samples of the intestine, lungs and other organs were placed in 10% buffered formalin and processed for histological examination. Microscopically, the duodenum had diffuse necrosis of the superficial mucosa, causing severe disruption of villous architecture with heterophil and mononuclear cell infiltration and occasional bacterial colonies. These areas of necrosis contained numerous specimens of *P. menurae* (Fig. 1). The bird with gross pulmonary lesions had several foci of granulomatous inflammation in the pulmonary parenchyma; no fungi or acid-fast bacilli were evident in these foci. There was some interstitial infiltration by lymphocytes. Bacteriologic culture of the intestines yielded a mixture of coliform bacteria and *Proteus* sp., while culture of the pulmonary lesions yielded no significant bacteria. Protozoa were not evident in intestinal smears.

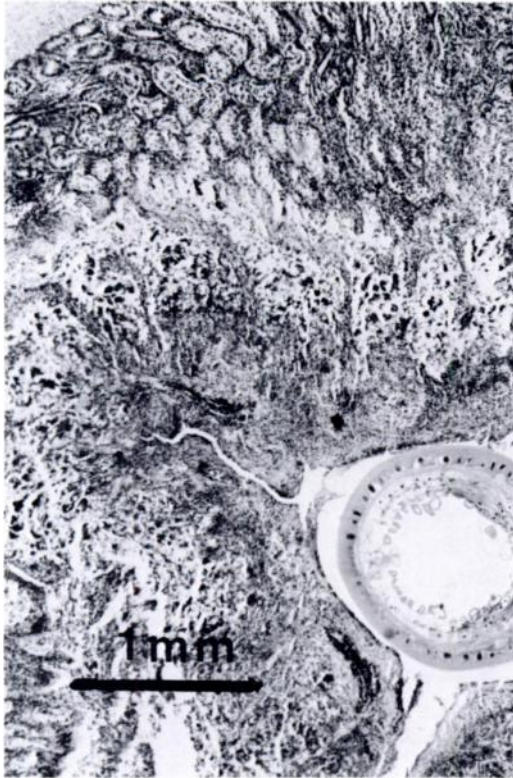


FIGURE 1. Necrosis of the duodenal mucosa of lyrebird associated with infections of *Plagiorhynchus menurae*. H&E.

Plagiorhynchus menurae is a parasite of uncertain taxonomic position and unknown life-cycle. However, other species of *Plagiorhynchus* sp. infecting birds have isopods, such as pill bugs (*Armadillidium* sp.), as the intermediate host (Moore, 1984). The infection of the intermediate host by acanthocephalans may induce behavioural patterns which render the invertebrate more susceptible to predation by the final

host (Moore, 1984). This species is known from lyrebirds in Victoria, New South Wales and Queensland, Australia (Johnston, 1912a, b; Johnston and Best, 1943).

Significant enteritis was associated with acanthocephalans in both birds. It is likely that the acanthocephalans were the primary cause of the intestinal lesions, although secondary bacterial infection may have contributed to the lesions. The cause of the lung lesions was not determined.

The diet and forest-floor habitat of lyrebirds exposes them to likely intermediate hosts of acanthocephalans. It appears that the acanthocephalan *P. menurae* is sufficiently pathogenic to debilitate intestinal function in the lyrebird. The few birds examined did not allow any indication of the potential impact of this disease on the lyrebird populations.

We thank Pam Whiteley, Rod Reece and Ken McColl for supply of birds and Nick Barton and Stan Edmonds for assistance in identifying the cestodes and acanthocephalans, respectively.

LITERATURE CITED

- JOHNSTON, T. H. 1912a. Notes on some entozoa. Proceedings of the Royal Society of Queensland 24: 64-91.
- . 1912b. Internal parasites recorded from Australian birds. Emu 12: 105-112.
- , AND E. W. BEST. 1943. Australian acanthocephala No. 4. Transactions of the Royal Society of South Australia 67: 226-235.
- MOORE, J. 1984. Altered behavioural responses in intermediate hosts—An acanthocephalan parasite strategy. American Naturalist 123: 572-577.

Received for publication 21 September 1988.