

17 skunks ≥ 3.0 yr old had damage, and most was moderate to severe.

The total number of worms extracted from skulls of six male skunks was correlated significantly with cranial damage class ($r^2 = 0.80$, 4 df, $P < 0.05$) (Table 2). Older skunks tended to have a higher proportion of male worms (weighted $r^2 = 0.64$, 4 df, $P = 0.06$).

Increased numbers of worms and more severe cranial damage were associated with older skunks, probably resulting from the progressive accumulation of worms over time (Kirkland and Kirkland, 1983, op. cit.). Kirkland and Kirkland (1983, op. cit.) found an average of 70–75% of skulls of adult skunks from across North America exhibited lesions (vs. 25–30% of non-adults), and that rates of damage were highest in regions of high precipitation.

These phenomena may be related to the mode of transmission of *Skrjabingylus* spp., since terrestrial gastropods are an obligate intermediate host whose abundance and distribution varies directly with environmental moisture.

This study was supported by the Forest Wildlife Populations and Research Group, Minnesota Department of Natural Resources and the U.S. Fish and Wildlife Service, Office of Endangered Species. We are grateful to R. K. Markl for field assistance, P. L. Coy for determining skunk ages, M. J. Pybus and M. W. Lankester for providing definitive identification of the nematodes, and D. Heisey, M. K. Lankester, M. J. Pybus, G. L. Kirkland and P. D. Karns for reviewing the manuscript.

Journal of Wildlife Diseases, 20(4), 1984, pp. 350–351
© Wildlife Disease Association 1984

***Renicola lari* Timon-David, 1933 from the Osprey, *Pandion haliaetus* (L.), from Alberta, Canada**

Murray J. Kennedy, Alberta Agriculture, Veterinary Services Branch, 6909 - 116 Street, Edmonton, Alberta T6H 4P2, Canada; and **Paul F. Frelrier**, Alberta Agriculture, Veterinary Services Branch, Airdrie, Alberta T0M 0B0, Canada

Adult Digenea belonging to the genus *Renicola* parasitize the kidneys of birds frequenting marine or brackish waters (Martin, 1982, Proc. Helminthol. Soc. Wash. 49: 19–21). Life cycles have been described by Stunkard (1964, Biol. Bull. 126: 467–489), Werding (1969, Mar. Biol. 3: 306–333), Martin (1971, Trans. Am. Microsc. Soc. 9: 188–194), and Prevot and Bartoli (1978, Ann. Parasitol. (Paris) 53: 561–575).

On 24 July 1983, a female osprey, in poor physical condition, was found in the Chain Lakes area in Alberta, Canada

(50°15'N, 114°13'W) by personnel of the Fish and Wildlife Division and taken to the Calgary Zoo for hospitalization. The bird died of avian cholera (*Pasteurella multocida*) on 7 September, and was submitted to the Veterinary Laboratory, Animal Health Division, Airdrie, Alberta for examination. The kidneys were removed at necropsy and preserved in 10% buffered formalin. Portions of kidney tissue were prepared for histological examination and the remainder dissected. Histological examination of kidney tissue revealed multiple cross-sections of trematodes (Fig. 1). The trematodes were normally present in pairs within dilated kidney tubules lined by cuboidal cells. In

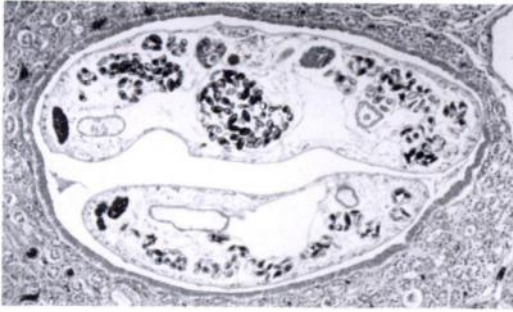


FIGURE 1. *Renicola lari* in kidney tubule of an osprey. H&E, $\times 113$.

the present report, the microscopic changes were similar to those described for *R. lari* Timon-David, 1933 in the herring gull (*Larus argentatus* Pontoppidan) by Stunkard (1964, op. cit.) and included compression of the parenchyma, dilation and obliteration of the tubule lumen containing parasites, with little or no host tissue reaction. These are the primary pathological features of *R. lari* infections in birds (Jacobson et al., 1980, J. Wildl. Dis. 16: 627–631). The effects of this parasite on the clinical status of the osprey were not determined, but it is conceivable that infections with large numbers of worms could serve as an additional stress causing poor condition or death of the host.

Numerous whole specimens recovered from tissues and stained with Semichon's acetocarmine were identified as *R. lari* following the description of Timon-David (1933, Bull. Inst. Oceanogr. (Monaco) 616: 1–16), Prevot and Bartoli (1978, op. cit.), McDonald (1981, Key to trematodes reported in waterfowl, U.S. Dept. Int. Res. Publ. 142, 156 pp.). Voucher specimens were deposited in the National Museums of Canada, Parasite Collection, Ottawa (NMCIC[P] Coll. Nos. 1984-0272, 0273). Timon-David (1933, op. cit.) first described *R. lari* from the kidneys of herring gulls from Marseilles, France. Since then,

it has been reported from Hungary (Matskaski, 1974, Parasitol. Hung. 7: 91–97), and Poland (Maksewski, 1964, Wiad. Parazytol. 10: 563–564) from naturally infected herring gulls and *Larus* sp., respectively. Prevot and Bartoli (1978, op. cit.) determined the life cycle and developmental stages experimentally in herring gulls and black-headed gulls (*L. ridibundus* L.).

The present report represents new geographical and host records for *Renicola lari* which suggest that this digenean is more widespread than previously believed.

Other species of *Renicola* have been reported from the United States: *R. brantae* McIntosh and Farr, 1952 from the Canada goose [*Branta canadensis* (L.)] (McIntosh and Farr, 1952, J. Parasitol. 38: 35–36); *R. hydranassae* Lumsden and Zischke, 1963 from the Louisiana heron [*Hydranassa tricolor* (Müller)] (Lumsden and Zischke, 1963, Z. Parasitenk. D. 22: 316–366); *R. glandoloba* Witenberg, 1929 from the laughing gull [*Larus atricilla* L.] and the common tern [*Sterna hirundo* L.] (MacInnis, 1966, Zool. Anz. 176: 52–68); (Byrd and Heard, 1970, J. Parasitol. 56: 483–497); *R. hayesannieae* Byrd and Kellogg, 1972 from the wild turkey [*Meleagris gallopavo* L.] (Byrd and Kellogg, 1972, J. Parasitol. 58: 99–103), and Canada: *Renicola* sp. from the common eider [*Somateria mollissima* (L.)] (Bishop and Threlfall, 1974, Proc. Helminthol. Soc. Wash. 41: 25–35), but none have been reported from the osprey. The only report of a renicolid (*R. pandioni* Sudarikov, 1947 and *R. undecima* Sudarikov, 1947) from osprey is from Gorkii Province, U.S.S.R. (Sudarikova, 1947, cited in Skrjabin, 1979, Trematodes of Animals and Man, Vol. 1., Amerind Publ. Co., New York, 407 pp.).